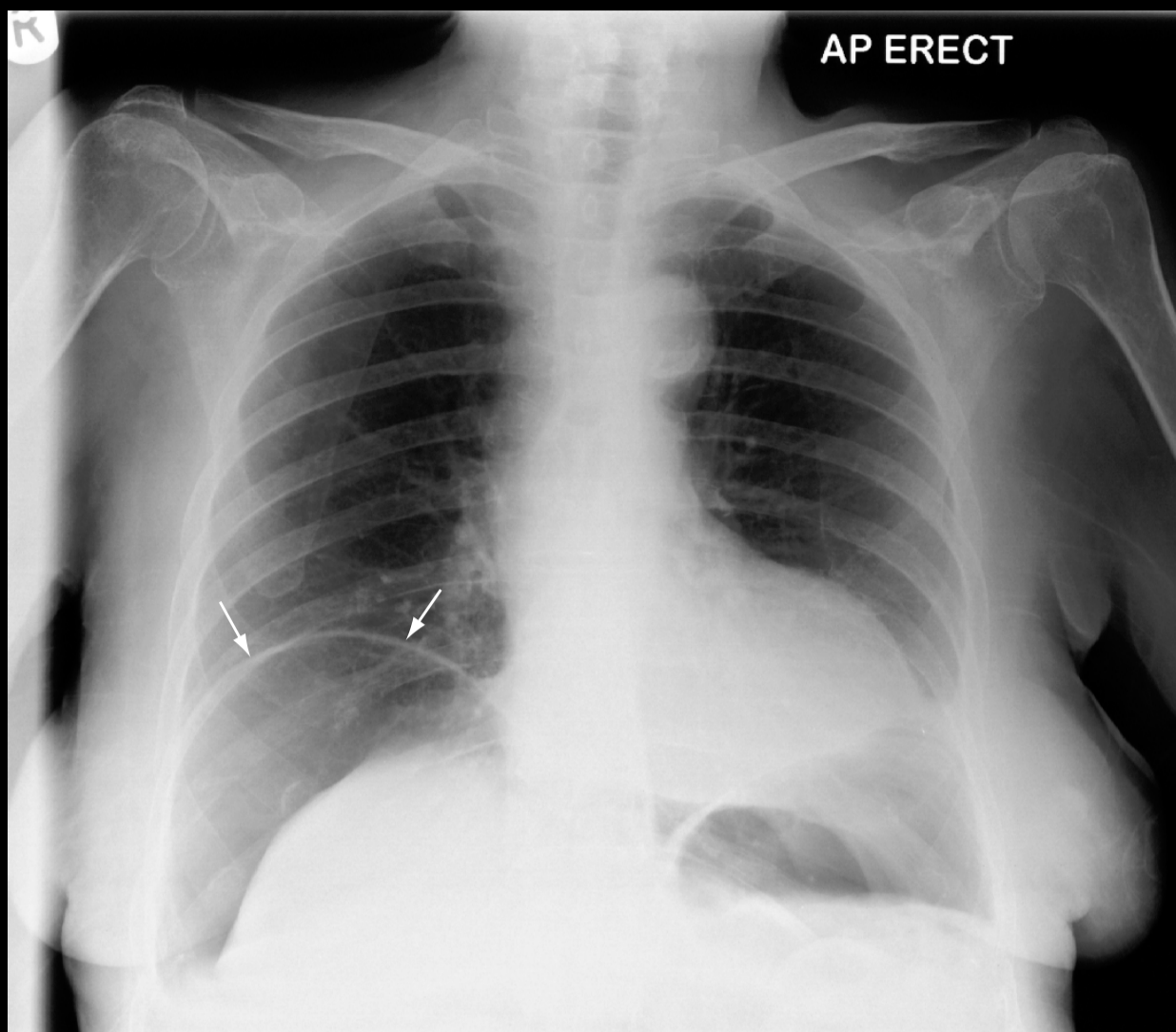


# Perforated duodenal ulcer on plain x-ray

Chest x-ray showing subdiaphragmatic gas (diaphragm arrowed)



Supine abdominal X-ray with both sides of the bowel wall visible (Riggler's sign, arrowed) signifying free intra-peritoneal gas.

